


– THE SML –

GUIDEBOOK

Developed for professional Ophthalmic Practitioners

THE MAGNIFIER IN THE EYE

Learn more at
www.maculalens.com



MEDI  NTUR

Chapter Overview

1. Introduction

- a. AMD worldwide
- b. SML history
- c. Multicentric study
- d. How do I start?

2. The SML

- a. Characteristics
 - I. Material
 - II. Design
- b. Functionality – Mode of Action
- c. Advantages of the SML

3. The SML Experience

- a. Pre-Operative
 - I. Indications and contraindications
 - II. Examination – Setting up a predictable outcome – level expectations
 - III. The SML Advisor
- b. Implantation
 - I. Step-by-Step Guide
 - II. Possible complications and recommendations
- c. Post-Operative
 - I. Patient training

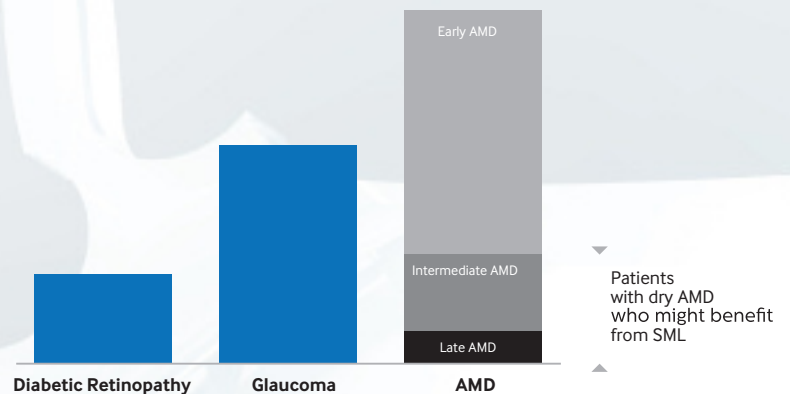
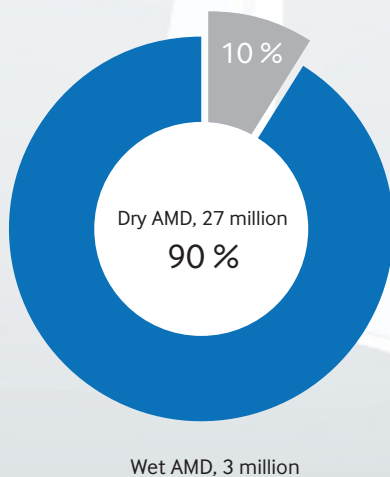
Just how common is AMD?

AMD is the **most common cause of irreversible blindness** in both developed and developing countries, particularly in people older than 60 years.

AMD is more common in women than men and people of Caucasian and Chinese ethnicity are more likely to be affected by the disease.

Approximately **30 million** humans are affected by the disease, around 90% of these have the **dry**, or non-exudative form of AMD.

Two thirds of patients with advanced AMD and a visual acuity of 0.3 or less are **pseudophakic** - these patients can benefit from the **SML**.



The most common causes of blindness in developed countries

Treatment of AMD

There have been significant advances in the treatment of exudative (**wet**) AMD with the introduction of anti-angiogenesis therapy, and patients now have effective treatment options that can prevent blindness and, in many cases, restore their vision.

HOWEVER,

currently there is **no medication available for dry AMD** and treatment possibilities are limited to low vision rehabilitation devices (low vision aids and low vision intraocular implants).

The **SML technology** was developed to enhance the quality of life of pseudophakic patients with **advanced dry AMD**. It can also be helpful for patients with other macular diseases, e.g. myopic maculopathy, diabetic retinopathy or certain hereditary retinal diseases.

SML HISTORY – THE INVENTORS

The SML is a joint innovation of **Prof. Gábor Scharioth** and **Medicontur Medical Engineering**, a medical device company with 30 years of focused experience with intraocular implants.

The SML was first implanted in 2013 and there have been over 500 commercial implantations worldwide since.



During my ophthalmological practice macular diseases have always been my special concern, especially Age-related Macular Degeneration. I had to find again and again that patients evaluate treatment outcomes differently from us doctors. While a patient maintains his ability to focus and orientate himself, he is usually not able to read anymore. These observations finally led to the development of our Macula Lens in cooperation with the Hungarian company Medicontur Medical Engineering.

Prof. Gábor B. Scharioth

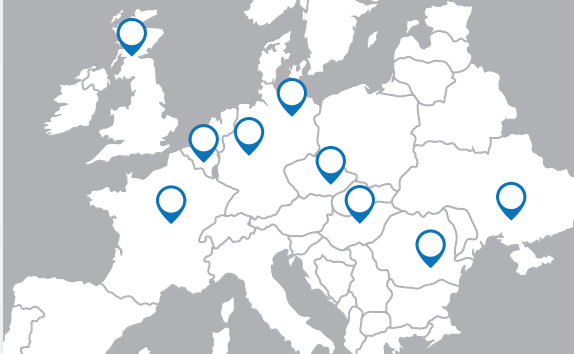

Medicontur Medical Engineering is an independent European company in existence since 1988. With more than 4 million intraocular implants produced and sold across 60 countries, we have been at the forefront of developing innovative solutions in material, design and optics.

The SML project gives AMD patients the chance to regain their lost abilities and to improve their quality of life. This is something that we, together with Prof. Gabor Scharioth, are very proud of.

Alexandra Kontur, MD, PhD
Scientific Director

Clinical Studies confirmed the efficacy and safety of the SML.



Quick facts:

- 8 countries
- 9 centers
- 106 eyes implanted in total

Conclusion of the clinical studies:

- **PREDICTABILITY** = Strong correlation between preoperative CNVA +6.0D at 15 cm and postoperative NVA at 15 cm
Preoperative testing:
 - Allows to predict postoperative results
 - Enables setting realistic expectations with patients
- Patients were satisfied or highly satisfied
- Improvement with time and training: NVA: D1 < D7 < M1: After 1 month near visual acuity was stable (unless the maculopathy worsened)
- **TRAINING**
 - Postsurgical training of patients is of utmost importance
 - Significantly improves outcome after surgery

Please note: If indications are set properly & patients are trained appropriately after surgery, results are good or excellent.

- 1 Scharioth GB. New add-on intraocular lens for patients with age-related macular degeneration. J Cataract Refract Surg. 2015; 41:1559-63.
- 2 Srinivasan S et al. Implantation of Scharioth macular lens in patients with age-related macular degeneration: results of a prospective European multicenter clinical trial. Poster at ESCRS 2016; Presentation at AAO 2016.
- 3 Nekolová J et al. The Scharioth macula lens: postoperative care and its importance for best results. Poster at ESCRS 2016.
- 4 Nekolová J et al. Scharioth Macula Lens: A new intraocular implant for low-vision patients with stabilized maculopathy - first experience. Biomed Pap Med Fac Univ Palacky Olomouc Czech Repub. 2017; 161:206-209.
- 5 Reiter N et al. Assessment of a new hydrophilic acrylic supplementary IOL for sulcus fixation in pseudophakic cadaver eyes. Eye 2017; 31:802-809.
- 6 Bereczki Á. Clinical results and patients satisfaction after implantation of 15 patients with Scharioth Macula Lens. Presentation at SHIOL 2017.

HOW DO I START?

To be successful with the SML there are some preconditions to guarantee an adequate setup:

- ? you work at a clinic or an outpatient surgery center
- ? you have experience with macular degeneration & low vision patients
- ? you are prepared for diagnosing low vision patients (available personnel & equipment)
- ? you have a trained doctor or optician to take care of low vision patients.
- ? you are a cataract surgeon
- ? you are a retinal specialist or you have a retinal specialist in your team
- ? you have OCT (for macular imaging) at the clinic
- ? **you have a doctor and/or an optician who will be dedicated for pre- and post-operative care and training of implanted patients or you cooperate or have an agreement with an organization taking care of low-vision patients.**



Our first SML Patient

What does it take to get happy patients?

1. Precise patient selection and indication (supported by the Medicontur Scientific Team + tools),
2. Alignment of expectations and reality
3. Postsurgical patient training!

SURGEONS ARE SATISFIED WITH THE OUTCOMES AFTER IMPLANTATION OF PATIENTS WITH SML



”I have found SML as a simple, safe and effective option to enhance the reading vision in patients with-age related macular degeneration.”

Sathish Srinivasan FRCSEd, FRCOphth, FACS
(Ayrshire Eye clinic, Ayr, Scotland, UK)



”SML - a new hope for patients with AMD, return to active life without stigmatization and for a reasonable price.”

Prof. MUDr. Pavel Rozsival, CSc
(Teaching Hospital, Charles University, Hradec Kralove, Czech Republic)



”Patient selection is paramount. In case of our meticulously selected macular patients the SML provided a good reading visual acuity. Patients were enthusiastic about the results - so was I.”

Prof. Zoltan Z. Nagy, MD, med.habil, DSC
(Semmelweis University, Budapest, Hungary)



”The SML is an important progress for AMD patients, to manage their daily routine.”

Anneliese Riehl, MD
(nordBLICK Augenklinik Bellevue, Kiel, Germany)



”An opportunity to change.”

Gustav Muus, Managing Director at the Eye Hospital Denmark

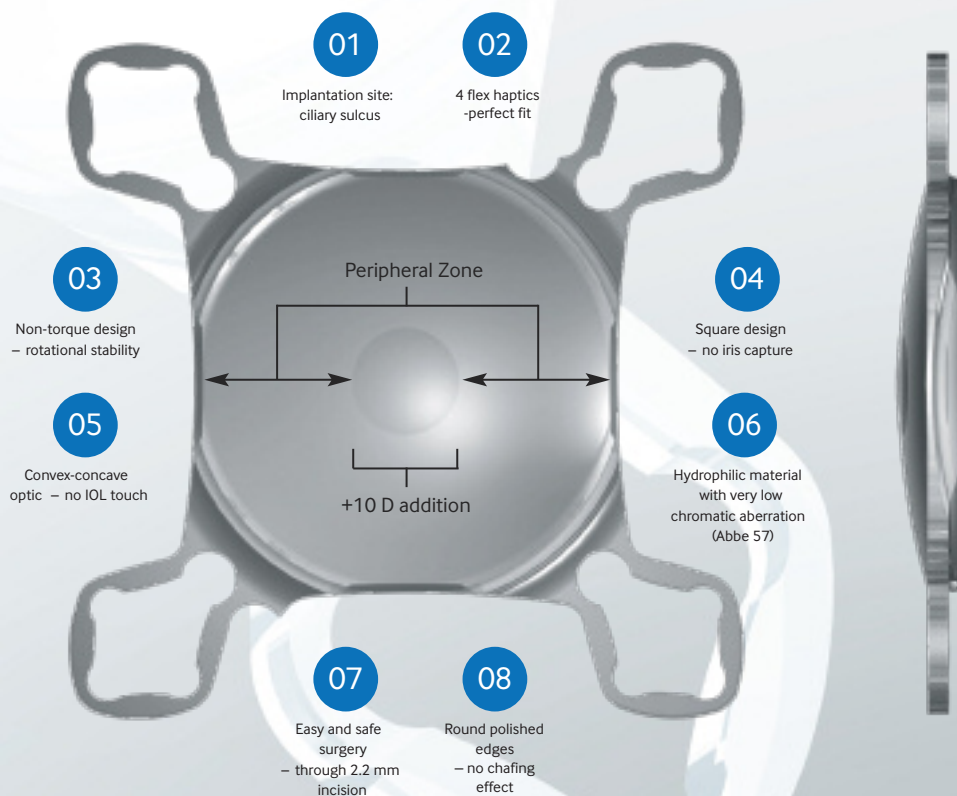
THE SML – CHARACTERISTICS

SML Material

- The SML is made of a copolymer of Hydrophilic and Hydrophobic Acrylic with 25% water content.
- It comes with a UV absorber and is also available with an additional blue light filter.

SML Design

- The SML is an intraocular sulcus lens that has a **bifocal design** with a central optical zone of 1.5mm in diameter.
- This optical zone provides a +10 diopter addition for patients.
- The peripheral zone is neutral, leaving the patient's distance vision and visual field unaffected.
- The special convex-concave optic maintains distance between the implants, preventing IOLs from touching each other.
- Due to its round polished edges the IOL has no chafing effect.
- The main square design prevents iris capture.
- The haptics' non-torque design ensures rotational stability.



SML is SAFE

The SML design was based on the **Medicentur Add-On Platform design** which has gained industry-wide attention for its excellent stability and ergonomic fit within the ciliary sulcus. The Add-On platform has been proven clinically (over 5.000 implantations) and in an in vitro study to be safe (Reiter et al. Assessment of a New Hydrophilic Acrylic Supplementary IOL for Sulcus Fixation in Pseudophakic Cadaver Eyes. Eye 2017; 31: 802-809)

Using the Near Triad Reflex: miosis – accommodation – convergence

Due to the effect of near vision miosis, the central optical portion that provides the magnified image will dominate when the patient focuses on near objects only, but will not influence far vision significantly when the patient focuses on distant objects through a dilated pupil.

Near vision:

The pupil is constricted (near vision miosis) and light rays pass through the central region of the SML, providing a magnified image on the macula (Figure 1).

Due to the high dioptric power of the central region, sharp vision is achieved at a distance of about 15 cm.

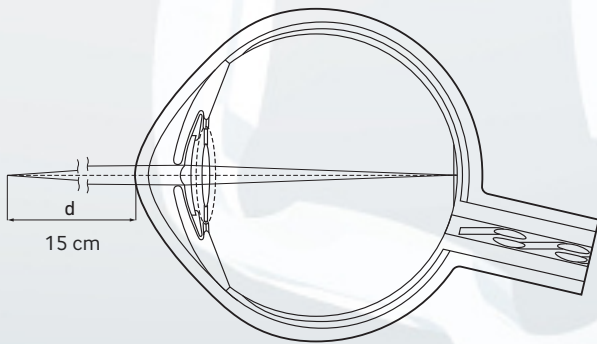


Figure 1:

Patient's eye with a constricted pupil
(near vision)

Distance vision:

The pupil is dilated when focusing on a distant object and thus light rays passing through the peripheral region of the SML will dominate over those passing through the central region (dashed lines) (Figure 2).

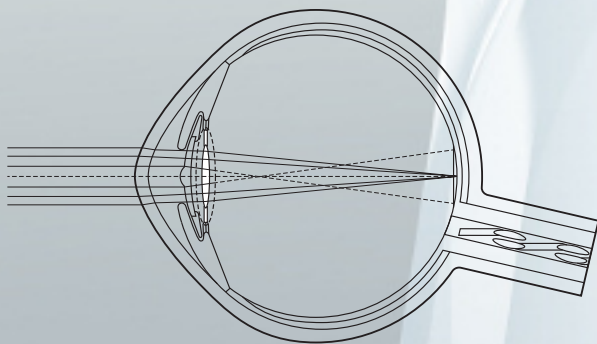


Figure 2:

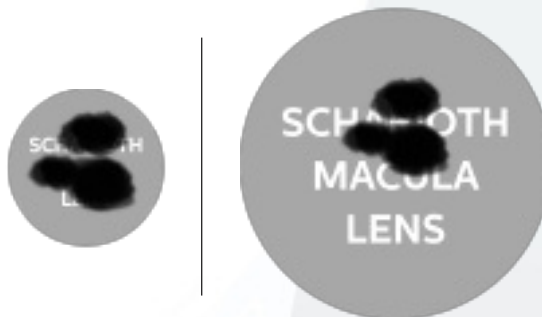Patient's eye with a dilated pupil
(distance vision)

The SML works through magnification (2.2 times)

The dark spots (scotomas) covering the text represent damaged macular areas.

The SML magnifies the text approximately 2 times but the size of the dark spots remains the same because the SML does not magnify the damaged parts of the macula. Thus, the SML enables patients with dry AMD to read the text.

Enlargement by **Zooming**:



Advantages of the SML

- Easy and safe surgery
- Small incision (2.2-2.4mm)
- No visual field reduction
- Unaffected distance vision
- Independent from lens status
- Quick adaptation
- Reversible
- Affordable

All examinations needed for a patient's regular follow-up after implantation with the SML (retina/macula visualization, OCT etc.) are **unaffected**

All treatments, if needed, can be performed **without limitations**:

- Intravitreal injections in case of exacerbation of maculopathy
- Laser treatment of retina
- YAG capsulotomy

How to choose a suitable patient?

KEY: MOTIVATION & SETTING REALISTIC EXPECTATIONS AND POST-SURGICAL TRAINING WITH THE PATIENT

Indications

The SML is recommended for motivated patients:

- With dry AMD and near vision difficulties
- With other stable retinal conditions (diabetic retinopathy, myopic retinopathy, some hereditary retinal diseases proven by OCT) – Please contact us for further information.
- Who are pseudophakic or candidates for cataract surgery
- Who show sufficient near vision improvement on near vision tests performed with +2.5D at 40 cm and with +6.0D at 15 cm
- BCDVA
 - equal or less than 0.32 decimal ETDRS (equivalent to 6/18)
 - equal or more than 0.1 (decimal ETDRS charts; equivalent to 6/60)
- * Please note that the patient may still benefit from the SML if outside of the above range. Please contact Medicontur to find out more.

Points to remember:

- The implanted eye should be the better seeing one
- Interval between OCT & surgery should not exceed 10 days
- Interval between cataract surgery and the SML implantation should be at least one month
- Simultaneous surgery (cataract extraction and Add-on lens implantation as a dual procedure) is possible, but not currently recommended by Medicontur
- Clear lens extraction and intracapsular IOL & SML implantation in one session is possible
- Each eye should be tested monocularly for distance (UCDVA & BCDVA) and near visual acuity

Examination and setting up a predictable outcome – level expectations

HOW TO SELECT A SUITABLE PATIENT?

- Preoperative CNVA needs to be examined as follows:
- Patients read at a distance of 40 cm with an addition of +2.5D placed over their distance prescription eyeglasses (examination A) and then at a distance of 15 cm with an addition of +6.0D placed over their distance prescription eyeglasses (examination B).
- The patient is a good candidate for the SML implantation if there is 3 or more lines of improvement between examination A and B.
- The patient may still benefit from SML implantation in case of 1 or 2 lines of improvement (please consult Medicontur or your local distributor)

IMPORTANT: based on these near vision tests, we can estimate the likely near visual acuity of the patients after implantation of the SML. It is important to communicate this with the patients and to set realistic expectations for them.

IMPORTANT:

- SML DOES NOT cure maculopathy.
- SML is a magnifier. It is like a low vision aid inside the eye.
- Exacerbation of maculopathy might occur any time after the implantation of the SML.
- The SML does not affect /limit any diagnostic or treatment procedures of exacerbated maculopathy.

Contraindications

- Active neovascular AMD/maculopathy
- Active iris neovascularisation
- Zonulopathy
- Subluxation of the primary IOL
- Shallow pseudophakic ACD (< 2.8 mm; from endothel)
- Narrow angle, i.e. < Schaefer grade 2
- Pigment dispersion syndrome
- Uveitis
- Pupillary abnormalities (photopic pupil less than 2.5 mm)
- Aphakia
- Progressive glaucoma
- Corneal diseases involving central cornea

The SML Advisor

The SML ADVISOR is your personal consultant and it helps you select the optimal patients who will BENEFIT from the SML.

- Easy to use
- Time saving (5 min)

Available at www.smladvisor.com

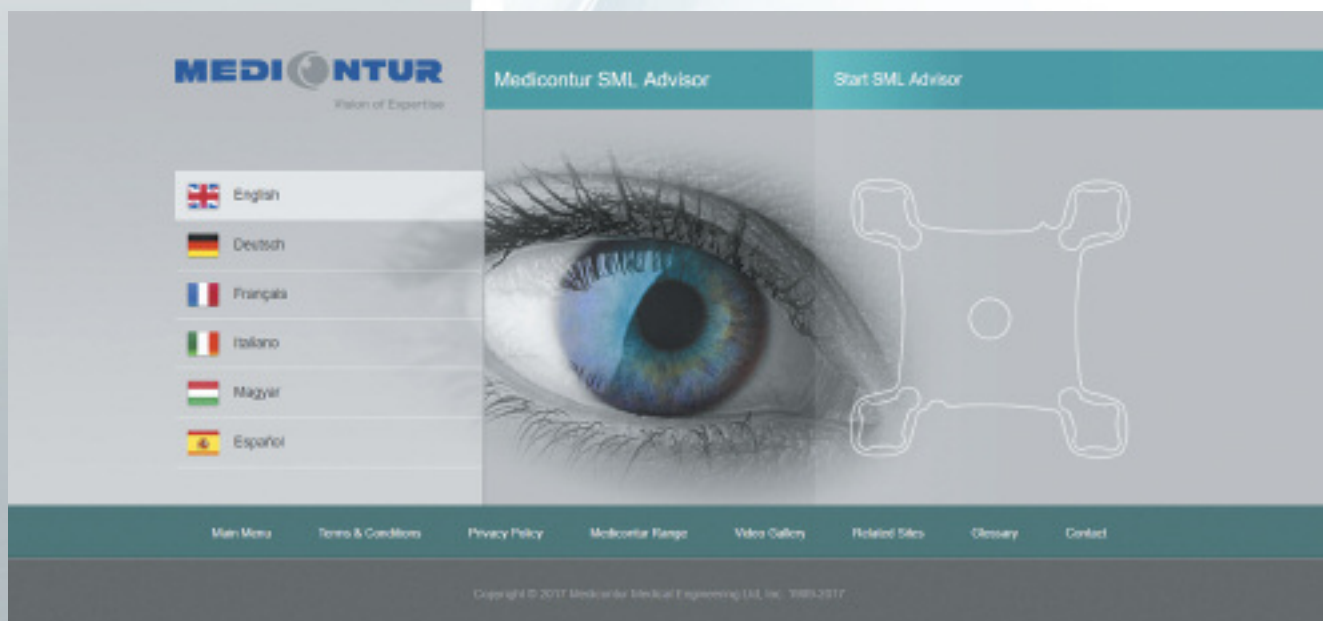
In 4 easy steps, the tool lets you:

- **Determine if a patient is suitable** for SML implantation
- Determine the **more suitable eye** for implantation as well as the optimal SML type (clear/yellow)
- **Estimate** the extent of **visual acuity improvement**
- Generate a **pdf and/or printout** that includes detailed patient data and the results of the evaluation, which you can then add to the **patient's records**.
- Generate, save, print or send the order form right away if the patient was evaluated as suitable for the implantation.

CAUTION:

Even the best online tools cannot substitute accurate measurements and the opinion of a specialist ophthalmologist.

If you have any further questions please contact us at scientific@medicentur.hu



Step-by-Step Guide

- Implantation in the ciliary sulcus is performed following cataract surgery but implantations may be performed simultaneously if necessary
- **Monocular** implantation in the **better-seeing eye**
- **Easy implantation** using a standard IOL injector through a 2.2 mm incision
- No extensive training is required – **minimal learning curve**



Possible complications and recommendations

Complications are not common but may occur

- WET AMD development: So far there is NO clear evidence that intravitreal injection of anti-VGEF may prevent decompensation/development of wet AMD after the implantation of SML under dry & stable AMD conditions. For this reason the preventive use of anti-VGEF is currently not recommended by Medicontur.
- SD-OCT macula is recommended to be performed before surgery, ideally no more than 10 days before surgery to avoid hidden / developing wet AMD.
- Inflammatory reaction in the anterior chamber. Anti-inflammatory drugs like corticosteroids (for up to 3 weeks after surgery) and NSAIDs (for up to 2 months after surgery) are recommended.
- Far vision disturbances (halos, glares). We recommend sunglasses and if these are not effective, we recommend so called Neutral Density Filter glasses. Pilocarpine can also be considered if sunglasses are not effective in reducing these symptoms.

TRAINING AFTER SURGERY IS OF UTMOST IMPORTANCE

Patients need to **practice** performing near vision **reading** tasks without the use of magnifying aids. This should be performed **2-3 times a day for at least 20 minutes** at a time during the first 4-8 weeks following SML implantation.

The eye without the SML implantation may need to be covered during the first few days after SML implantation when reading.

The **reading material needs to be held at approximately 15–18 cm** from the patient's eye.

Good lighting conditions and high contrast reading materials are recommended.

A dedicated and experienced low vision expert is necessary for achieving optimal results after surgery.

The adaptation is quick: it usually takes 2-5 weeks after surgery.

DO NOT FORGET:

**READING DISTANCE IS APPROXIMATELY
15–18 cm (6") FROM THE PATIENT'S EYE**



MEDIONTUR
PIONEERS IN VISION CARE

Dear Patient,
You have been implanted
with the SML – the Scharioth
Macula Lens.

Please hold this sheet at approximately
15 cm (6") from your operated eye
to read further instructions below.

These instructions provide useful information that will help your recovery after the implantation. Train your eyes daily to get accustomed to SML. Spend at least 2 times 20 minutes every day reading a newspaper or book. **Remember: you need to hold the text at approx. 15 cm from your operated eye when reading.**

Do not touch or rub your eye. This may result in corneal abrasions, which can cause severe pain. You may resume non-exhaustive activities such as quick walking, watching TV or using the computer immediately after surgery. You may shower or bath when you get home, but avoid getting water in your eye during the first two weeks. Do not use creams, lotions and make-up around the operated eye either. Do not swim, lift weights, or engage in activities risking direct impact to your eye during the first two weeks after surgery.

It is necessary to check the healing process carefully to prevent infections or other complications, thus your ophthalmologist should give you exact dates for regular check-up after the surgery. She/he will help you also detailed explain you how to train your eyes to speed-up rehabilitation of your vision. After the surgery, you may experience Eye-pain, eye redness, increased light sensitivity, itching, blurred or distorted vision, decreased visual acuity, visual disturbances.

If any of these symptoms persist for more than one day, please contact your doctor immediately. If you have further questions, do not hesitate to ask them – we are always available to help you.

Contact

Mediontur Medical Engineering Ltd., Hercegalmi Road, 2072 Zsámbék, Hungary, www.mediontur.com



NOTES



A series of horizontal dotted lines for taking notes, spanning the width of the page.

NOTES



A series of horizontal dotted lines for taking notes, overlaid on a faint background illustration of a person in a white lab coat.

NOTES

A large, faint, light blue graphic of a pair of safety goggles is overlaid on the page, extending from the top right towards the bottom center. The page contains horizontal dotted lines for writing notes.

REFERENCES



1. WHO causes of blindness. 2008.
2. Agarwal A, Lipshitz I, Soosan J, Mandeep L, Rahul T, Kumar AD, Agarwal A.: Mirror telescopic intraocular lens for age-related macular degeneration. Design and preliminary clinical results of the Lipshitz macular implant. *J Catar Refr Surg.* 2008; 34; 87-94.
3. A.Calabrèse, JB Bernard, L. Hoffart, G. Faure, F. Barouch, J.Conrath, E. Caster: Wet versus Dry Age-Related Macular Degeneration in Patients with Central Field Loss: Different Effects on Maximum Reading Speed. *Investigative Ophthalmol & Visual Science*, April 2011, Vol.52, No. 5.
4. Lipshitz, I, Loewenstein, A, Reingewirtz, M, and Lazar, M. An intraocular telescopic lens for macular an intraocular telescopic lens for macular degeneration *Ophthalmic Surg Lasers.* 1977; 28: 513–517.
5. Age-Related Eye Disease Study Research Group. Potential public health impact of age-related eye disease study results; AREDS report no. 11 *Arch Ophthalmol.* 2003; 121: 1621–1624.
6. Rosner, M., Ben-Simon, G., and Sachs, D. Feasibility and safety of laser treatments in eyes with an intraocular implantable miniature telescope. *J Cataract Refract Surg.* 2003; 29: 1005–1010.
7. Agarwal, A. Consultation section: cataract surgical problems. *J Cataract Refract Surg.* 2007; 33: 183–185.
8. Riusala, A., Sarna, S., and Immonen, I. Visual Function Index (VF-14) in exudative age-related macular degeneration of long duration. *Am J Ophthalmol.* 2003; 135: 206–212.
9. Kaskaloğlu, M., Üretmen, Ö, and Yağcı, A. Medium-term results of implantable miniaturized telescopes in eyes with age-related macular degeneration. *J Cataract Refract Surg.* 2001; 27: 1751–1755.
10. Alió, J.L., Mulet, E.M., Ruiz-Moreno, J.M. et al. Intraocular telescopic lens evaluation in patients with age-related macular degeneration. *J Cataract Refract Surg.* 2004; 30: 1177–1189.
11. Koziol, J, Peyman, G.A, Cionni, R et al. Evaluation and implantation of a teledioptric lens system for cataract and age-related macular degeneration. *Ophthalmic Surg.* 1994; 25: 675–684.
12. Peli, E. The optical functional advantages of an intraocular low-vision telescope. *Optom Vis Sci.* 2002; 79:225-233.
13. Goldstein, H. The reported demography and the causes of blindness throughout the world. *Adv Ophthalmol.* 1980; 40: 1-99.
14. Hengerer FH, Artal P, Kohnen T, Conrad-Hengerer I. Initial Clinical Results of a New Telescopic IOL Implanted in Patients With Dry Age-Related Macular Degeneration. *J Refract Surg.* 2015;31(3):158-162.
15. K. Michalska-Malecka, A. Kabiesz, M. Nowak, D. Spiewak: Age related macular degeneration – challenge for future: Pathogenesis and new perspectives for treatment.
16. Friedman DS, O’Colmain BJ, Muñoz B, Tomany SC, McCarty C, de Jong PT, Nemesure B, Mitchell P, Kempen J. Eye Diseases Prevalence Research Group. Prevalence of age-related macular degeneration in the United States. *Arch Ophthalmol.* 2004;122:564–572.
17. Vingerling JR, Dielemans I, Hofman A, Grobbee DE, Hijmering M, Kramer CF, de Jong PT. The prevalence of age-related maculopathy in the Rotterdam Study. *Ophthalmology.* 1995;102:205–210.
18. Klein R, Knudtson MD, Lee KE, Gangnon RE, Klein BE. Age-period-cohort effect on the incidence of age-related macular degeneration: the Beaver Dam Eye Study. *Ophthalmology.* 2008;115:1460–1467.
19. Klein R, Klein BE, Lee KE, Cruickshanks KJ, Gangnon RE. Changes in visual acuity in a population over a 15-year period: the Beaver Dam Eye Study. *Am J Ophthalmol.* 2006;142:539–549.
20. Parmeggiani F, Romano MR, Costagliola C, Semeraro F, Incorvaia C, D’Angelo S, Perri P, De Palma P, De Nadai K, Sebastiani A. Mechanism of inflammation in age-related macular degeneration. *Mediators Inflamm.* 2012;2012:546786.
21. Tien Y. Wong, Xiang Li, Xinyi Su, Gemmy C. Cheung, Ching-Yu Cheng: The number and distribution of People with Age-Related Macular degeneration Worldwide in 2020 and 2040: A Systematic Review and Hierarchical Bayesian Meta-Analysis. Program NO: 220; Poster Board Nu:D0065; ARVO 2013.
22. Wan Ling Wong, Xinyi Su, Xiang Li, Chui Ming G Cheung, Ronald Klein, Ching-Yu Cheng, Tien Y. Wong: Global prevalence of age related macular degeneration and disease burden projection for 2020 an 2040: a systematic review and meta-analysis. *Lancet Glob Health* 2014;2:e106-16; publishe on-line January 3, 2014.
23. Yalin Mu, Manli Zhao, Guangming Su: Stem cell-based therapies for age-related macular degeneration: current status and prospects. *Int J Clin Exp Med* 2014;7(11):3843- 3852.
24. Scharioth GB, “Add-on IOLs for Vitrectomized Silicone oil-filled Eyes,” *Retinal Physician* May 2014; 11:31–33. Available at: <http://www.retinalphysician.com/articleviewer.aspx?articleID=111129>.
25. Sauder G, Cordes A. Scope of applications and experience record with a new generation of add-on IOLs: the A4W lens. *Ophthalmol-Chirurgie* 2012; 24(suppl. 2):1–6. Available at: http://www.1stq.de/media/raw/A4W_Englisch_AddOn_OphthalmolChirurgie_engl.pdf.
26. Scharioth GB. New add-on intraocular lens for patients with age-related macular degeneration. *J Cataract Refract Surg.* 2015; 41:1559-63.

Material. Design. Optics.



MEDICONTUR
Medical Engineering Ltd
export@medicontur.com
www.medicontur.com

HEAD OFFICE
Herceghalmi Road
2072 Zsámbék
Hungary

INTERNATIONAL OFFICE
Chemin des Aulx 18
1228 Plan-les-Ouates
Switzerland / Geneva